

Advances In Prosthodontics™

New Findings & Best Practices for Cosmetic & Restorative Dentistry

INSIDE THIS ISSUE

CASE SUMMARY:

Do You Have a Patient With This Situation? (see photos on right)

Complete Details on this Full Mouth Reconstruction... pages 1-3

HAVE A LAUGH:

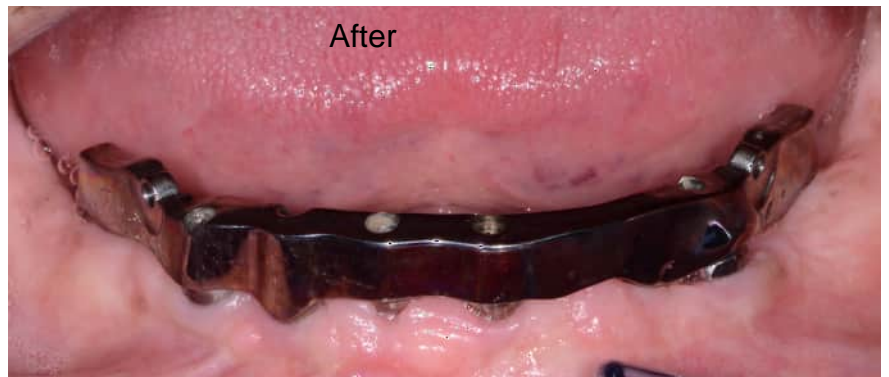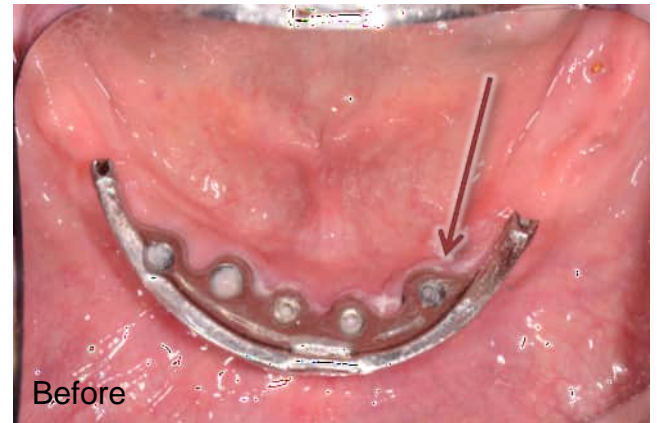
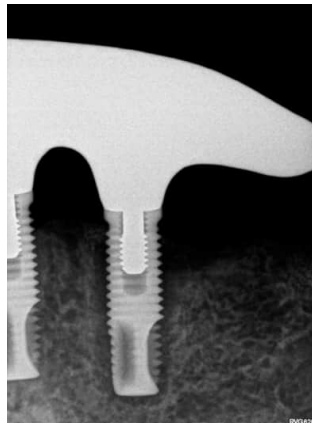
You Know You're a Dentist When You See This... page 3

COMPLEX CASES:

Dr. Chao's Specialized Training, Prosthodontic Treatments, and What Patients Think of Her Work... page 4

© Same Media Group, LLC

Do You Have a Patient With a Failing Implant?



Here's the story of a patient who was referred from another dental professional...

If you have a patient with several missing, broken or worn teeth—or a failing restoration—they may be a candidate for oral reconstruction with the assistance of a Prosthodontist.

Read more on the next page...

◆ Do you want another opinion on a complex case? Or to meet and share ideas?

There are many ways we can help each other by working together on complex cases and by sharing knowledge and experience. I'd like to invite you to lunch, dinner, or an office meeting to talk more about a difficult procedure or to share ideas. With your reputation for quality dental care, and my experience with restorative treatments, we can work together on advanced cases and both benefit! I'm looking forward to talking with you on the phone or meeting in person.

Please call or email my office with specific days and times when you are available for a meeting...

CASE SUMMARY: Salvaging and remaking a Bar-Retained Implant Overdenture

by Dr. Maggie Chao, Prosthodontist

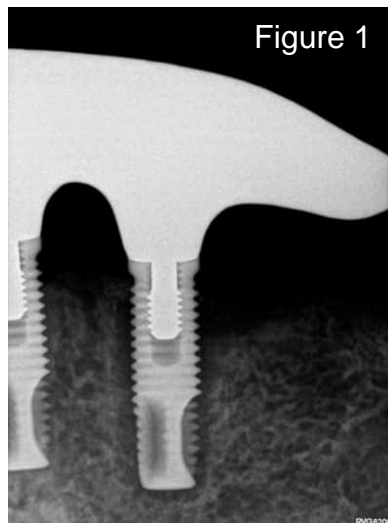


Figure 1

Patient “Jerry” was referred to me by another dental professional in the area who was busy with their patient load, and Jerry’s needs were more complex than they wanted to manage. I had the pleasure of meeting Jerry at his initial consultation to discuss his situation. He was 69-years-old, and was told by the referring dentist that one of his implants was failing (Figure 1).

Jerry had a 5-implant bar-retained Overdenture made 20 years ago in New York. Implant #21 was exhibiting bone loss. Clinically, the tissue around the implant appeared healthy but pus/exudate could be expressed (Figure 2).

We took a 3-D CBCT scan in our office (Figure 3) and determined that there was adequate space to remove the failing implant, immediately place an angulated implant, AND we could give him a FIXED provisional—all in one day! So that is what we did.

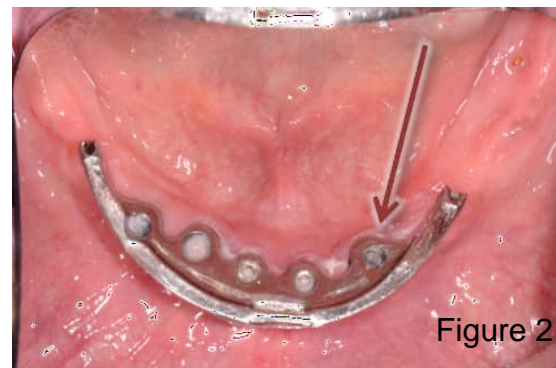


Figure 2

PHASE I of treatment — Surgery day:

- Implant #21 was removed,
- An angulated implant #20 was placed (Figure 4), and
- His lower overdenture was converted into a temporary hybrid. After 20 years of wearing a removable prosthesis, he was able to ditch his denture and go home with a fixed bridge.

PHASE II of treatment — After 4 months of healing:

- We began making his final prosthesis. We told Jerry that he had the choice of either staying with a fixed bridge or going ‘back’ to a bar-overdenture.
- He selected the bar-overdenture because despite all of our oral hygiene instructions and provided aids, Jerry could not keep a hybrid clean.
- I chose to fabricate for him a CAD-CAM bar and a milled suprastructure (Figure 5 on next page).

Continued on next page...

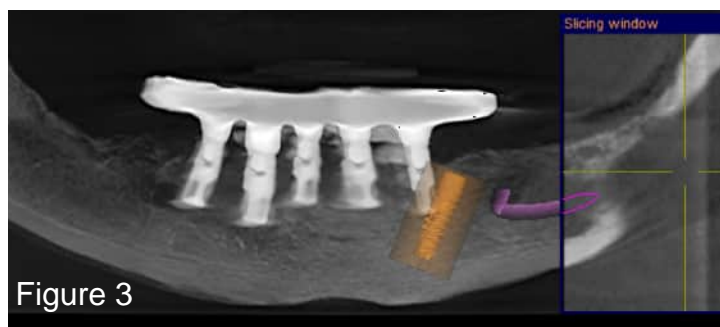


Figure 3

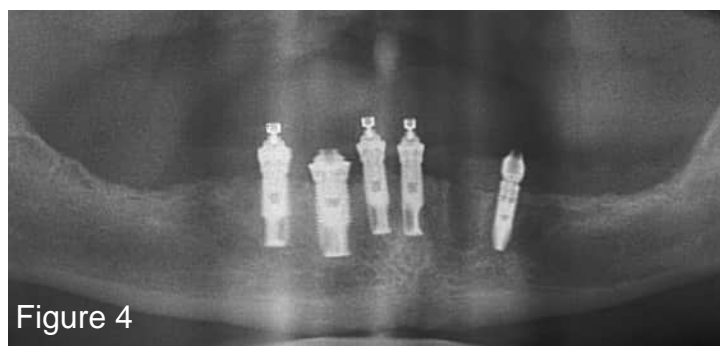


Figure 4

Do you have a patient in Jerry’s situation? Or another complex case?

If you have a question about a case and want another opinion, give my office a call. Or, if there’s a case that you want to work together on, please fill out and send in the enclosed referral form.

My office and I will take great care of your patient and keep you informed. Dental professionals refer to me as **The Complex Case Specialist™** because I perform complex cases every day.



Continued from previous page...

Jerry was thrilled with his new teeth. He reported that virtually no food gets under the overdenture and there were no sore spots or adjustments needed.

I gave him my full warranty (that I give to all referred patients) and sent him back to the referring doctor's office for regular hygiene visits, noting that he come to our office for an annual exam and maintenance.

Reflections about this case:

- If you are not familiar with this type of restoration, it is an entirely implant-supported prosthesis— it is *not* tissue supported. The framework fits passively onto the bar and utilizes two precision attachments to lock the bridge onto the bar providing the feel and function of a fixed prosthesis.
- Looking back, one key factor that made this case successful was the fact that I was able to find the parts necessary to adapt his original implants (Nobel Biocare) into a new prosthesis. Would I have been able to do this if his original dentist used a different implant system 20 years ago? In reality— probably not! Are all implants the same? They all work, but do they all offer the same flexibility in restorative options? And do they come from a company that will still be here in 20 years? Jerry's case reminded me that our implant choices today will continue to affect our patients in the future.
- Also, this case highlights how excellent communication and respect amongst colleagues and team members are all essential for a successful outcome. For this case, the general dentist was best prepared to advise on the patient's oral health history, while an oral surgeon performed the extraction and implant placement. As a prosthodontist, my role was planning the multi-stage treatment and fabricating the final prostheses.

If you have comments or questions, please email me at: drchao@pleasantonpros.com. I would love to hear if you have protocols that worked for similar patients, or if you have questions about how I treated Jerry from this case summary.

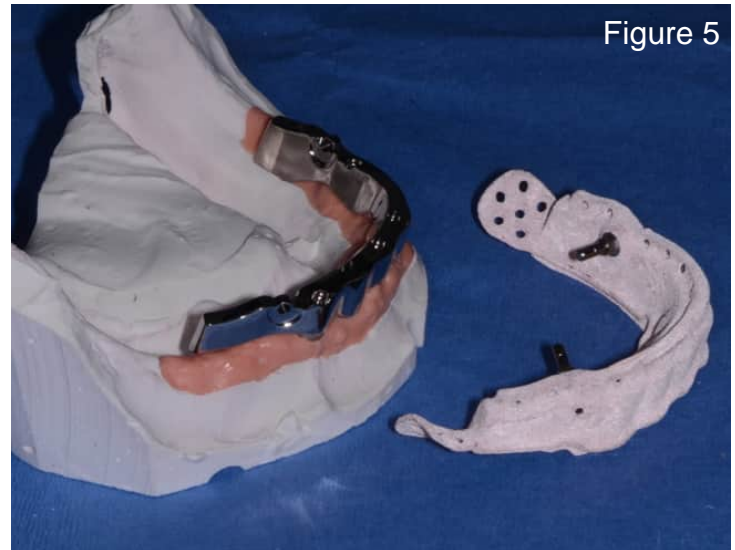
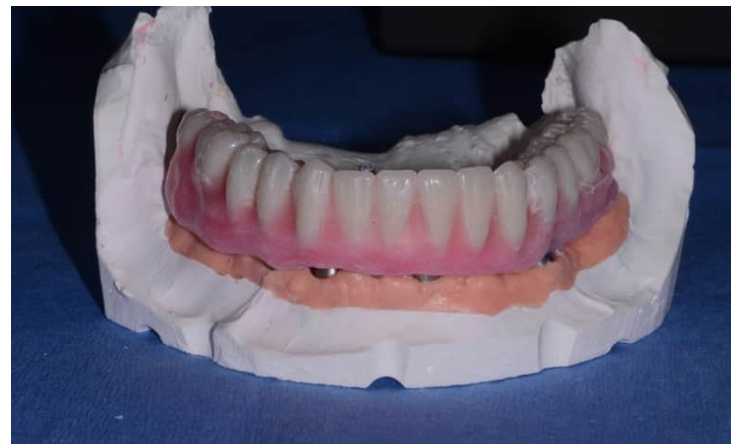
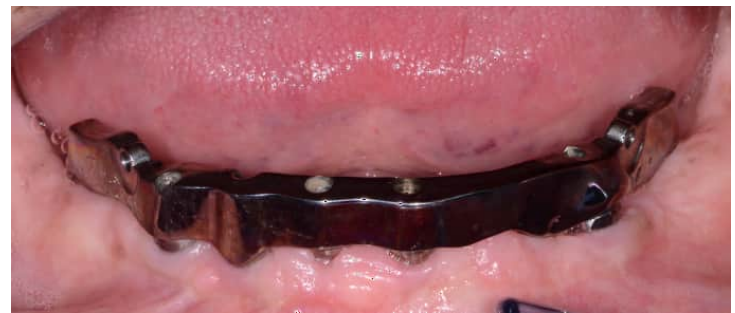

Figure 5



Have A Laugh: You know you're a dentist when...you see the bat-signal to help!



I hope I made you smile during your busy day!

I take the care of patients referred to me very seriously, including knowing how to educate them so they feel comfortable.

It's my goal to help every patient understand even the most difficult procedures, so they can regain the function and esthetics they desire.

Dr. Maggie T. Chao

DMD, Prosthodontist ♦ The Complex Case Specialist™



Dr. Maggie Chao works with dental professionals near Pleasanton and the Walnut Creek areas.

About Pleasanton Prosthodontics:

Pleasanton Prosthodontics is a specialty practice limited to fixed and removable prostheses, dental implants, and all phases of esthetic dentistry. Dr. Chao's prosthodontic training and private practice experience make treatments of complex cases more successful, including the following examples:

- Patients with ill-fitting dentures, severely worn or damaged teeth can receive a single dental implant or a full arch of natural-looking teeth.
- Patients who have suffered from traumatic injury, congenitally missing teeth, or a chronic condition can receive oral prostheses, which may be a combination of dental implants, crowns, bridges, or veneers.
- Patients with severe neglect of their oral health can receive a full reconstruction to restore function & esthetics.

A Special Message To Fellow Dental Practitioners:

“As the referring dentist, you know your patient's mouth and have key insight into your patient's needs. I want to work with you to provide your patients with the best possible treatment outcomes. I will treat your patient in a manner that will reflect well on you and strengthen your relationship with your patient. I am here to make you look good! When your patient's care is completed, they are referred back to your office for their ongoing dental care. I am grateful for your collegueship and trust with your patients!”

◆ Why other dental professionals work with a Prosthodontist

Prosthodontists are specialists in implant, esthetic, and reconstructive dentistry.

1. You have a patient requiring complex treatment outside of your typical practice.

Examples include patients with vertical dimension discrepancies, severely resorbed ridges, inadequate interarch space, TMJ, severe bruxism, traumatic tooth loss, or congenital abnormalities.

2. You have a patient with complex needs that may drain your time.

If your patient may require treatment from several specialists, Prosthodontists can help because they are trained to appropriately stage and manage complex treatment plans.

3. You have a demanding patient who wants perfect esthetics.

Examples include patients with a high smile line or needing a single tooth replacement in the esthetic zone. A Prosthodontist is trained in selecting the best solutions for high-demand patients.

4. You have a question and want to discuss a case with a colleague to ease your mind.

A Prosthodontist can be an excellent resource for you to ask questions because they are trained in many types of complicated treatments. For example, you may want to consult or refer to a Prosthodontist for complex implant-supported restorations. A Prosthodontist can work with you or complete the treatment for you to achieve the best in both function and esthetics.