

Advances In Prosthodontics™

New Findings & Best Practices for Cosmetic & Restorative Dentistry

INSIDE THIS ISSUE

CASE STUDY:

Do You Have a Patient With This Situation?
(see photos on right)

Complete Details on this Full Mouth Reconstruction...
pages 1-3

HAVE A LAUGH:

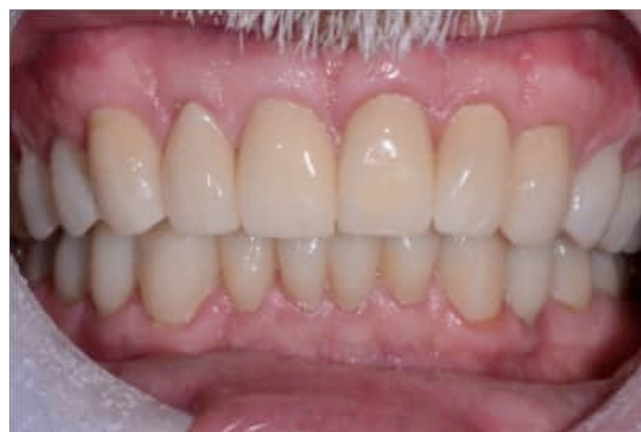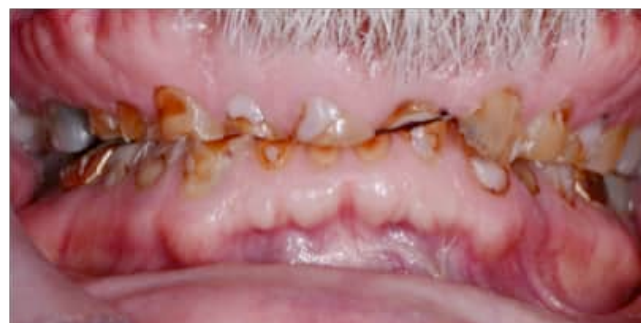Gollum from the "Lord of the Rings" movie...
page 3

COMPLEX CASES:

Dr. Chao's Specialized Training, Prosthodontic Treatments, and What Patients Think of Her Work...
page 4

© Sams Media Group, LLC

Do You Have a Patient Like This?



Here's the story of a patient who was referred from another dental professional...

If you have a patient with several missing, broken or worn teeth, they may be a candidate for a full mouth reconstruction with the assistance of a Prosthodontist.

Read more on the next page...

◆ Do you want another opinion on a complex case? Or to meet and share ideas?

There are many ways we can help each other by working together on complex cases and by sharing knowledge and experience. I'd like to invite you to lunch, dinner, or an office meeting to talk more about a difficult procedure or to share ideas. With your reputation for quality dental care, and my experience with restorative treatments, we can work together on advanced cases and both benefit! I'm looking forward to talking with you on the phone or meeting in person.

Please call or email my office with specific days and times when you are available for a meeting...

CASE STUDY: Full Mouth Reconstruction

Dr. Maggie Chao, Prosthodontist

Patient Tom (not his real name) was referred to me by another dental professional in the area who was busy with their patient load, and Tom's needs were more complex than they wanted to manage.



A self-professed “non-smiler,” Tom is a seasoned gentleman who was told in his 20's that he would need to have a full mouth reconstruction when he was older. Now that his children are grown and his career is nearing an end, he was ready to take care of his tooth “nubs.” He was not in pain and was functioning well -- neither eating nor speaking was problematic. Tom recently started to feel a little

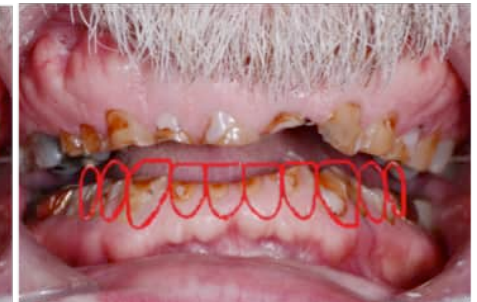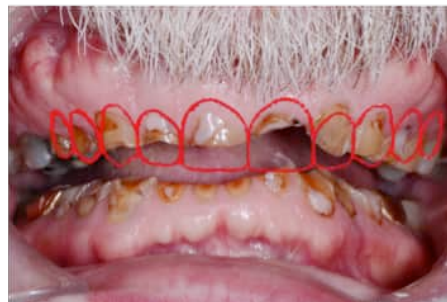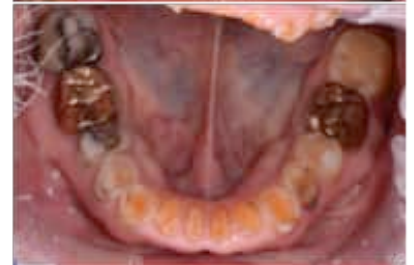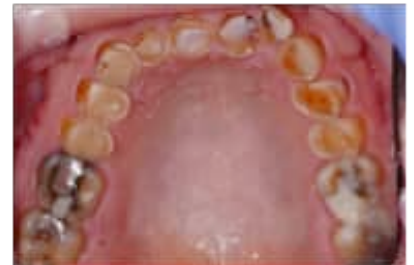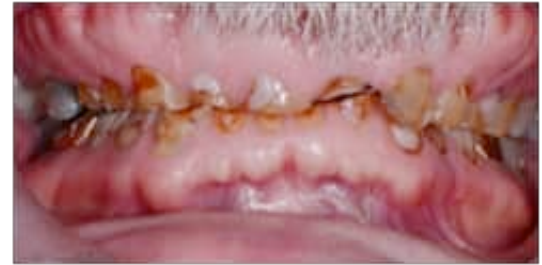sensitivity to biting on #3 and 14. His dentist recognized that placing crowns on worn teeth would not be predictable. I was asked to help give Tom some treatment alternatives so he could understand both the short-term and long-term effects of his current decisions.

While Tom had significant tooth structure loss, it was apparent that his anterior teeth exhibited more wear than his posterior teeth. There appeared to be compensatory supraeruption of his mandibular anterior teeth so his occlusal plane was maintained. In Maximum Intercusation, it appeared that Tom had Angles Class I Canines and Molars bilaterally. There were sizeable buccal exostoses which would need to be addressed.

As a prosthodontist, I have experience planning multi-stage treatment plans over several months, sometimes years, and can coordinate with a patient's general dentist and other dental specialists.

Utilizing Frank Spear's template for Facially Generated Treatment Planning, it was determined that I could accomplish our goals using a combination of periodontal crown-lengthening surgery and crowns to re-establish Tom's occlusion.

Continued on next page...



Do you have a patient in Tom's situation? Or another complex case?

If you have a question about a case and want another opinion, give my office a call. Or, if there's a case that you want to work together on, please fill out and send in the enclosed referral form.

My office and I will take great care of the patient and keep you informed. Dental professionals refer to me as **The Complex Case Specialist™** because I perform complex cases every day.



Continued from previous page...

Tom healed well after exostoses removal and crown-lengthening. He said that the most unsettling thing about this whole process was the idea of his gums getting “peeled back.” But, he said it didn’t hurt as much as he expected and he was very pleased with the results. He felt that he has a second chance to use “God’s given implants” rather than titanium ones! Here he is 6 weeks after surgery (top right)...

I then provisionalized him in Centric Relation. Lo and behold -- there’s now a Class II occlusal pattern! I kept Tom in provisionals for 6 months to evaluate his tolerance to his new Vertical Dimension of Occlusion. To the right is a picture of his provisionals...

Tom gave me the green light that he was comfortable and asymptomatic. He still doesn’t find that he is a natural smiler. But that’s ok! I consider this grin (below) to be an indication of a job well done...



Here’s his final result at the end of this full mouth reconstruction (left and middle right)...

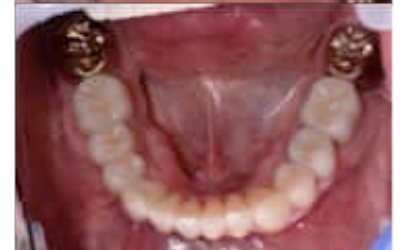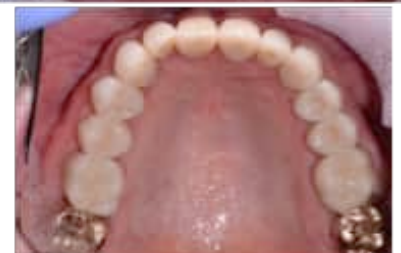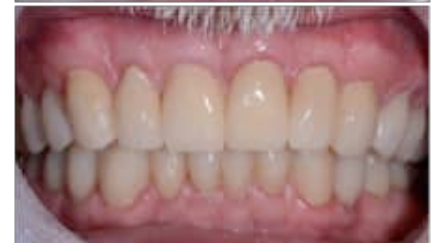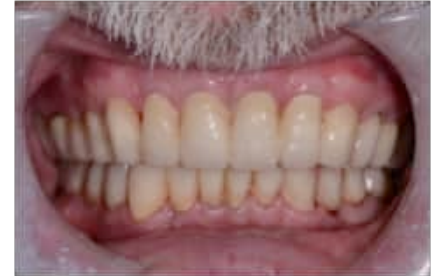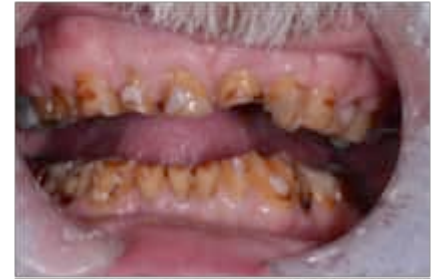A quick note on prevention and maintenance:

I follow UCSF’s recommended CAMBRA protocol for Tom and use Carifree products to help him stave off recurrent caries. Tom denied having any history of ulcers, reflux, or a love for

acidic beverages. While attrition was the primary etiology, it makes sense that malocclusion and possible erosive factors came together to create this pattern of wear. Now, through the help of the referring office, we need to help him maintain it!

I gave him my full warranty (that I give to all referred patients) and sent him back to the referring doctor’s office for regular hygiene visits, noting that he come to our office for an annual exam and maintenance.

If you have comments, please email me at: drchao@pleasantonpros.com I would love to hear if you have protocols that worked for similar patients, or if you have questions about how I treated Tom from this case study.




Have A Laugh: Gollum from the “Lord of the Rings” movie...



I hope I made you smile during your busy day!

I take the care of patients referred to me very seriously, including knowing how to educate them so they feel comfortable.

It’s my goal to help every patient understand even the most difficult procedures, so they can regain the function and esthetics they desire.



Dr. Maggie T. Chao

DMD, Prosthodontist ♦ The Complex Case Specialist™



About Pleasanton Prosthodontics:

Pleasanton Prosthodontics is a specialty practice limited to fixed and removable prostheses, dental implants, and all phases of esthetic dentistry. Dr. Chao's prosthodontic training and private practice experience make treatments of complex cases more successful, including the following examples:

- Patients with ill-fitting dentures, severely worn or damaged teeth can receive a single dental implant or a full arch of natural-looking teeth.
- Patients who have suffered from traumatic injury or cancer can receive maxillofacial prostheses and artificial substitutes for oral and facial tissue.
- Patients with severe neglect of their oral health can receive a full reconstruction to restore function & esthetics.

What patients say about Dr. Chao's dental work:

"I have been in this business a long time (I'm a dental hygienist) and I know how difficult it is to find a doctor you can trust. Dr. Chao is the kindest, caring, gentle and experienced doctor I trust! I was having issues with my dental implant crowns placed by another doctor. I went to Dr. Chao to have the work completed correctly. She delivered beautiful crowns in a timely and anxiety free appointment." – Karla S.

"The most caring dentist I've met. I had very poor fitting dentures. After going to her, I knew she was the expert I was looking for. She uses the latest technology and sure enough, she made a perfect fit." – Ernie C.

"I took my mom to appointment with Dr. Chao earlier this week. Both my mom and I were beyond impressed with Dr. Chao patience and kindness. She took all the time needed to explain her findings. You could imagine at 83 this is a stressful process but my mom was more than comfortable. Dr. Chao is very gentle with her hands, which made my mom feel safe." – Francee C.

Learn more at: PleasantonPros.com

◆ Why other dental professionals work with a Prosthodontist

Prosthodontists are specialists in implant, esthetic, and reconstructive dentistry.

1. You have a patient requiring complex treatment outside of your typical practice.

Examples include patients with vertical dimension discrepancies, severely resorbed ridges, inadequate interarch space, TMJ, severe bruxism, traumatic tooth loss, or congenital abnormalities.

2. You have a patient with complex needs that may drain your time.

If your patient may require treatment from several specialists, Prosthodontists can help because they are trained to appropriately stage and manage complex treatment plans.

3. You have a demanding patient who wants perfect esthetics.

Examples include patients with a high smile line or needing a single tooth replacement in the esthetic zone. A Prosthodontist is trained in selecting the best solutions for high-demand patients.

4. You have a question and want to discuss a case with a colleague to ease your mind.

A Prosthodontist can be an excellent resource for you to ask questions because they are trained in many types of complicated treatments. For example, you may want to consult or refer to a Prosthodontist for complex implant-supported restorations. A Prosthodontist can work with you or complete the treatment for you to achieve the best in both function and esthetics.