

Advances In Prosthodontics™

New Findings & Best Practices for Cosmetic & Restorative Dentistry

INSIDE THIS ISSUE

CASE SUMMARY:

Do You Have a Patient With This Situation?
(see photos on right)

Details for this Full Mouth Reconstruction...

pages 1-3

HAVE A LAUGH:

Gollum from the "Lord of the Rings" movie...

page 3

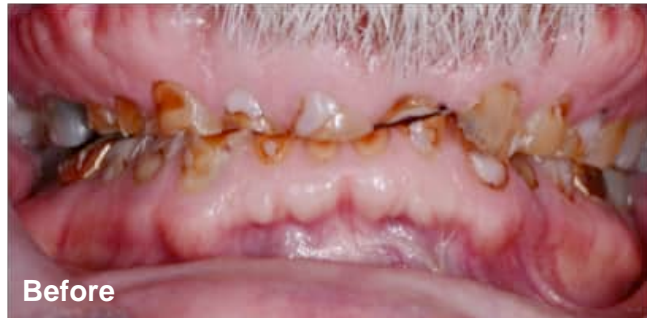COMPLEX CASES:

Dr. Chao's Specialized Training & Skill Make These Treatments More Successful...

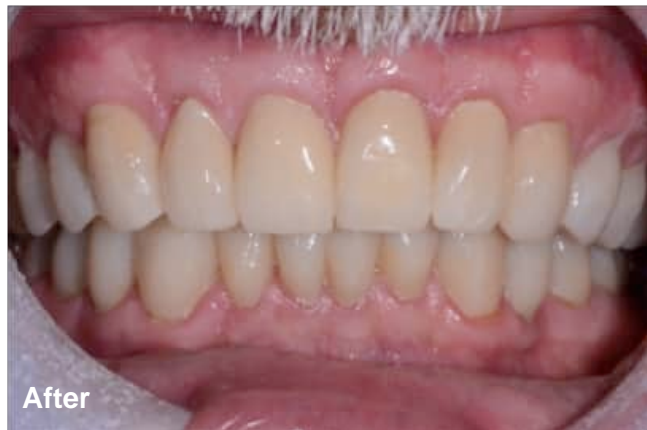page 4

© Sams Media Group, LLC

Do You Have a Patient With Severe Wear?



Before



After

Here's the story of a patient who was referred from another dental professional...

If you have a patient with several missing, broken or severely worn teeth — they may be a candidate for oral rehabilitation with the assistance of an advanced Prosthodontist.

Read more on the next page...

◆ Do you want another opinion on a complex case? Or to talk and share ideas?

There are many ways we can help each other by working together on complex cases and by sharing knowledge and experience. With your reputation for quality dental care, and my experience with restorative treatments, we can work together on advanced cases and both benefit! If you'd like to discuss a treatment, or talk on the phone about how we can help each other, please call or email my office with specific days and times when you're available.

Prosthodontic Publication

Want to see recent issues?

Stay informed on new findings and best practices for cosmetic and restorative dentistry. See more examples of complex cases online at:

AdvancedProsthodontist.com / Chao

CASE SUMMARY: Full Mouth Reconstruction

by Dr. Maggie Chao, Prosthodontist

Patient “Mike” was referred to me by another dental professional in the area who was busy with their patient load, and Mike’s needs were more complex than they wanted to manage.



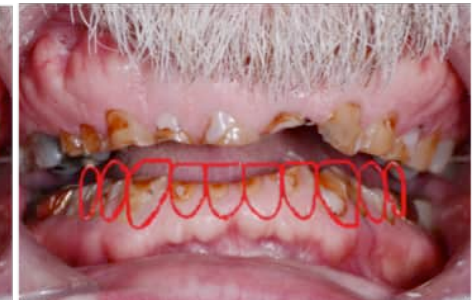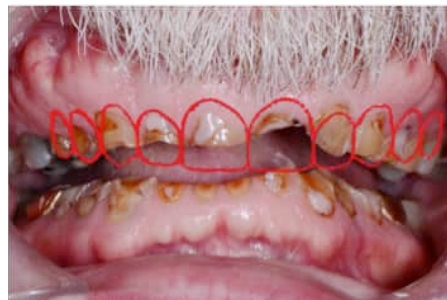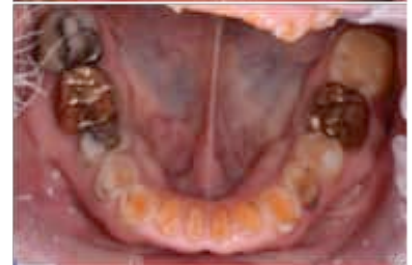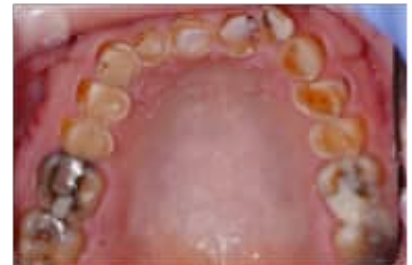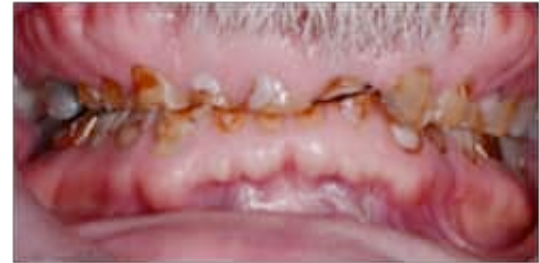A self-professed “non-smiler,” Mike is a seasoned gentleman who was told in his 20’s that he would need to have a full mouth reconstruction when he was older. Now that his children are grown and his career is nearing an end, he was ready to take care of his tooth “nubs.” He was not in pain and was functioning well — neither eating nor speaking was problematic. Mike recently started to feel a little

sensitivity to biting on #3 and 14. His dentist recognized that placing crowns on worn teeth would not be predictable. I was asked to help give Mike some treatment alternatives so he could understand both the short-term and long-term effects of his current decisions.

While Mike had significant tooth structure loss, it was apparent that his anterior teeth exhibited more wear than his posterior teeth. There appeared to be compensatory supraeruption of his mandibular anterior teeth so his occlusal plane was maintained. In Maximum Intercuspation, it appeared that Mike had Angles Class I Canines and Molars bilaterally. There were sizeable buccal exostoses which would need to be addressed.

As a prosthodontist, I have experience planning multi-stage treatments and can coordinate with a patient’s general dentist and other dental specialists.

Utilizing Frank Spear’s template for Facially Generated Treatment Planning, it was determined that I could accomplish our goals using a combination of periodontal crown-lengthening surgery and crowns to re-establish Mike’s occlusion.



Continued on next page...

◆ Do you have a patient in Mike’s Situation? Or another complex case?

If you have a question about a case and want another opinion, give my office a call. Or, if there’s a case that you want to work together on, please fill out and send in the enclosed referral form.

My office and I will take great care of your patient and keep you informed. Dental professionals refer to me as **The Complex Case Specialist™** because I perform complex cases every day.

Mike healed well after exostoses removal and crown-lengthening. He said that the most unsettling thing about this whole process was the idea of his gums getting “peeled back.” But, he said it didn’t hurt as much as he expected and he was very pleased with the results. He felt that he has a second chance to use “God’s given implants” rather than titanium ones! Here he is 6 weeks after surgery (top right)...

I then provisionalized him in Centric Relation. Lo and behold — there’s now a Class II occlusal pattern! I kept Mike in provisionals for 6 months to evaluate his tolerance to his new Vertical Dimension of Occlusion. To the right is a picture of his provisionals...

Mike gave me the green light that he was comfortable and asymptomatic. He still doesn’t find that he is a natural smiler. But that’s ok! I consider this grin (below) to be an indication of a job well done...

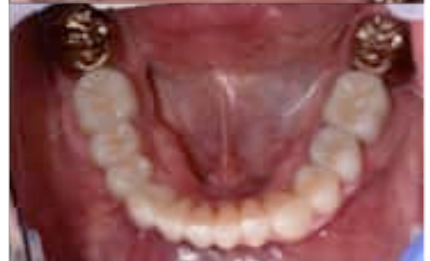
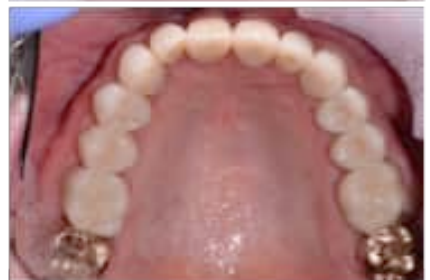
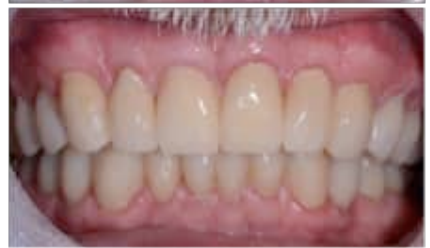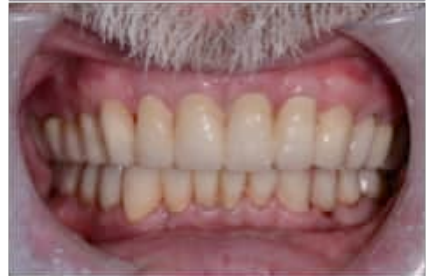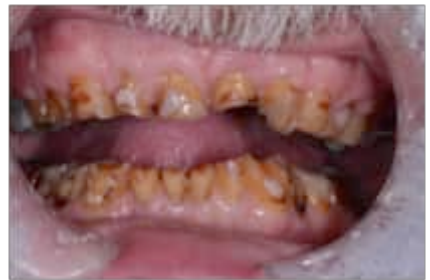Here’s his final result at the end of this full mouth reconstruction (left and middle right)...

A quick note on prevention and maintenance:

I follow UCSF’s recommended CAMBRA protocol for Mike and use Carifree products to help him stave off recurrent caries. Mike denied having any history of ulcers, reflux, or a

love for acidic beverages. While attrition was the primary etiology, it makes sense that malocclusion and possible erosive factors came together to create this pattern of wear. Now, through the help of the referring office, we need to help him maintain it!




I gave Mike my full warranty when I sent him back to the referring office for regular hygiene visits, noting that he come to our office for an annual exam and maintenance. I give all referred patients a warranty and refer them back to the general dentist for regular hygiene unless advised otherwise by the referring office, depending on the patient and treatment. If you have questions about my prosthodontic protocols, please email me at:

drchao@pleasantonpros.com

◆ **Have A Laugh:** Gollum from the “Lord of the Rings” movie...

I hope I made you smile during your busy day! I take the care of patients referred to me very seriously, including knowing how to educate them so they feel comfortable. I specialize in the treatment of complex cases, usually involving several procedures over months of care.

The next time you see a challenging case, please feel free to call me and we can discuss treatment planning or I can help you with any part of the treatment. My goal is to be a resource for your office by helping manage difficult and time-consuming procedures, restoring the function and esthetics that the patient desires, then referring them back to your office for their ongoing care.



Dr. Maggie T. Chao

DMD, Prosthodontist ♦ The Complex Case Specialist™



Dr. Maggie Chao works with dental professionals near the Pleasanton and Walnut Creek areas to restore the smiles and confidence of patients facing a difficult diagnosis.


About Pleasanton Prosthodontics:

Pleasanton Prosthodontics is a specialty practice limited to fixed and removable prostheses, dental implants, and all phases of esthetic dentistry. Dr. Chao's extensive prosthodontic training and private practice experience make treatments of complex cases more successful, including the following examples: Patients with ill-fitting dentures, severely worn or damaged teeth can receive a single dental implant or a full arch of natural-looking teeth.... Patients who have suffered from traumatic injury, congenitally missing teeth, or a chronic condition can receive oral prostheses, which may be a combination of dental implants, crowns, bridges, or veneers.... Patients with severe neglect of their oral health can receive a full reconstruction to restore function & esthetics.

PleasantonPros.com/doctor-referral

There are 2 ways to use this section of Dr. Chao's website to make treatment communication easier, help patients, and do less administrative work:

- 1) **Online Referral Form** is fast and secure, and
- 2) **Collaborator** that allows sharing of documents, radiographs, CT scans, and messages... organized and available to all colleagues working on a case... also HIPAA compliant with no software to install - simply create a password and log on anytime you want to view / update info. It's free to use!



The digital lab at Pleasanton Prosthodontics...
digital waxups,
printed models, and
occlusal guards

◆ Why other dental professionals work with a Certified Prosthodontist

Prosthodontists are specialists in implant, esthetic, and reconstructive dentistry.

1. **You have a patient requiring treatment outside your typical scope of practice.**
Examples include patients with vertical dimension discrepancies, severely resorbed ridges, inadequate interarch space, severe bruxism, traumatic tooth loss, or congenital abnormalities.
2. **You have a patient with complex needs that may drain your time.**
If your patient may require treatment from several specialists, Prosthodontists can help because they are trained to appropriately stage and manage complex treatment plans.
3. **You have a demanding patient who wants perfect esthetics.**
Examples include patients with a high smile line or needing a single tooth replacement in the esthetic zone. A Prosthodontist is trained in selecting the best solutions for high-demand patients.
4. **You have a question and want to discuss a case with a colleague to ease your mind.**
A Prosthodontist can be an excellent resource for you to ask questions because they are trained in many types of complicated treatments. For example, you may want to consult or refer to a Prosthodontist for complex implant-supported restorations. A Prosthodontist can work with you or complete the treatment for you to achieve the best in both function and esthetics.